

MINISTRY OF HEALTH OF THE REPUBLIC OF UZBEKISTAN
CENTRE FOR MEDICAL EDUCATION
ANDIJAN STATE MEDICAL INSTITUTE

CONGENITAL DIAPHRAGMATIC
HERNIA IN CHILDREN

Teaching manual for professors - teachers and students 4-7 courses of pediatric faculty
of medical schools

ANDIJAN – 2014

MINISTRY OF HEALTH OF THE REPUBLIC OF UZBEKISTAN
CENTRE FOR MEDICAL EDUCATION
ANDIJAN STATE MEDICAL INSTITUTE

"APPROVED"
Chairman of the Scientific Advisor
Andijan state medical Instit ,
Professor: A.K. SHADMANOV
"24" IX 2014
Protocol № 2

"APPROVED"
Board Chairman of the Problem
Commission for surgery
Professor: F.N. NISHONOV
"24" IX 2014
Protocol № 7

CONGENITAL DIAPHRAGMATIC
HERNIA IN CHILDREN

Teaching manual for professors - teachers and students 4-7 courses of pediatric faculty
of medical schools

33V AD11
JOH I MAZORAT INDEXSIYA
INCHOSTON
31 - XII 01/314 Насиба
2014 Y.

In the instructional manual describes the modern view of the etiopathogenesis of congenital diaphragmatic hernia in children, described clinical features, diagnosis, differential diagnosis and treatments.

Teaching aids designed for professors - our faculty and students, 4 to 7 courses of pediatric faculty of medical schools.

AUTHORS:

N.A. Akbarov - Ph.D., Associate professor of the Pediatric surgery and
anesthesiology - intensive care "Andijan state medical institute

A.A.Gafurov - MD, Head. department "Pediatric surgery and
anesthesiology - intensive care "Andijan state medical institute

K.L. Qosimov -assistant department "Pediatric surgery and
anesthesiology - intensive care Andijan state medical institute

R.M. Akbarova -assistant department "Pediatric" Andijan state medical institute

REVIEWERS:

M.M. Aliev - MD., professor of "Faculty surgery children "Tashkent pediatric
medical institute

B. S. Rahimov – Ph.D., Associate professor of the " Pediatric and surgery
anesthesiology intensive care "Andijan state medical institute

Teaching aid discussed at the Central methodical commission Andijan state
medical institute in 2014 « 14 » 09 № 1 protocol.

Teaching aid approved by the Scientific Council of Andijan state medical institute
2014 « 14 » 09 № 1 protocol.

Secretary of the Scientific council, associate professor:

H.A. HUSANOVA.

Theme name: Congenital diaphragmatic hernia in children

Venue classes: Department of "Pediatric surgery and anesthesiology and intensive care," surgical departments AODMMTS

Equipment classes: Case patients multimedia, slides, x-rays, posters.

Estimated lesson time: 6:00

Session Purpose: To teach students diagnostic clinics and principles of treatment of congenital diaphragmatic hernia in children.

Learning objectives:

1. Classification of congenital diaphragmatic hernia in children
2. Clinic congenital diaphragmatic hernia in children
3. Diagnosis of congenital diaphragmatic hernia in children
4. Differential diagnosis of congenital diaphragmatic hernia in children
5. Methods of study of congenital diaphragmatic hernia in children
6. Methods of treatment of congenital diaphragmatic hernia in children

The student should know:

1. Classification of congenital diaphragmatic hernia in children
2. Clinic congenital diaphragmatic hernia in children
3. Diagnosis of congenital diaphragmatic hernia in children
4. Differential diagnosis of congenital diaphragmatic hernia in children
5. Methods of study of congenital diaphragmatic hernia in children
6. Methods of treatment of congenital diaphragmatic hernia in children
7. Complication of congenital diaphragmatic hernia in children

The student should be able to:

1. Collect detailed history pediatric patients with congenital diaphragmatic hernia.
2. Clinical evaluation of congenital diaphragmatic hernia
3. Evaluation of the results of laboratory and radiological studies pediatric patients with congenital diaphragmatic hernia.
4. Able to conduct X - ray contrast study of gastro - intestinal tract in children with congenital diaphragmatic hernia.
5. Able to perform differential diagnosis of congenital diaphragmatic hernia in children.

Motivation: Congenital diaphragmatic hernia in children frequent and often lead to serious condition and can result in fatality. Therefore, training of students to the principles of early diagnosis and timely adequate treatment of congenital diaphragmatic hernia in children is important.

THE COURSE IS TAUGHT:

Diaphragmatic hernia is called displacement of abdominal organs into the chest cavity through natural or abnormal opening in the septum phrenic (diaphragm). Unlike other sites hernia diaphragmatic hernia does not always contain the entire set of such prerequisites as the hernial sac and hernial.

Incidence of this disease is difficult to establish. Some hernias manifest themselves immediately after birth, such as false hernia, others - after months or years, often a true hernia of the diaphragm, and others - sometimes in the elderly, such as hiatal hernia or retrosternal diaphragm. Nevertheless, all these types of hernias can occur at any age, including neonates.

According to various world centers of neonatal frequency of this disease in newborns ranges from 1:2500 to 1:5000. However, if the statistics include stillbirths, the true incidence of the disease may be about 1 to 2000 births. At this age, about 9% of the patients is observed from the movement of the abdomen to the chest through the rear slit-shaped defect, which is usually located on the left. Bilateral false hernia observed in 3.5% of cases and is usually incompatible with life. Other diaphragmatic hernia in infants is rarely found, only 2-5% of cases.

At older ages, more frequent hiatal hernia, then hernia diaphragmatic cupola, and rarely - retrosternal hernia. It is believed that hiatal hernia affects about 0.5% of the adult population.

It should be noted that in recent years, with the X-ray studies for various indications, in asymptomatic children have been identified with respect to many cases limited protrusion aperture or true hernia.

Treatment of diaphragmatic hernia in children, especially rapid, often as, for example, false hernias in infants for emergency indications. In other cases, can be

observed and treated conservatively, as is done with hiatal hernia. Results of surgical treatment are mixed. The highest mortality rate, despite all the medical advances, there remains in neonates undergoing surgery for false hernia of the diaphragm.

CLASSIFICATION OF CONGENITAL DIAPHRAGMATIC HERNIA IN CHILDREN (BY S.YA.DOLETSSKY, 1960)

1. The actual diaphragm hernia
 - A. Flexing thinning area of the diaphragm (the true hernia)
 - a) protrusion of a limited part of the dome
 - b) a large protrusion of the dome
 - c) The full protrusion of one dome (relaxation)
 - B. Defects of the diaphragm (false hernia)
 - a) a slit-like rear defect
 - b) a significant defect
 - c) the absence of the dome of the diaphragm

2. Hernias of the anterior diaphragm

- a) front hernia (hernia true)
 - b) frenoperikardialnye hernia (hernia false)
 - c) retrograde frenoperikardialnye hernia (hernia false)
3. Hiatal hernia (hernia true)
 - a) esophageal
 - b) paraesophageal

In our opinion in clinical practice is the most convenient to use classification, where congenital diaphragmatic hernia are divided into the following types, depending on their location.

Anatomical classification of congenital diaphragmatic hernias in children

1. Hernias rear of the diaphragm (false, transient)
2. Hernias diaphragm dome (true, sometimes false)
3. Hernias of the anterior diaphragm
 - a) retrosternal (true)

b) frenoperikardialnye (false)

4. Hiatal hernia (true)

a) esophageal

b) paraesophageal

REAR HERNIA OF THE DIAPHRAGM

Hernia rear of the diaphragm may be false, and, much more rarely, transient. Entrance gate hernia is a slit-like aperture in the wall surface defect lumbocostal department (Bogdaleka gap). In 85-90% of cases it occurs on the left. The defect can have different sizes, and the smaller the defect, the more pronounced is the muscle of the roller aperture residues on its costal margin. Usually roller is well expressed at the rear edge of the costal arch and disappears in the side part. Hernial sac often absent, and the abdominal organs are in direct contact with hypoplastic lungs. In rare cases (15-20%), they can be separated from the light remains the parietal pleura or peritoneum (transitional form hernia). In these cases, after being relegated organs in the abdomen, the bag should be excised. Otherwise, residual cyst can form, squeezing easy.

Most often in the pleural cavity displaced spleen, omentum, small intestine and colon, left kidney. Less often, usually for large defects - the stomach and part of the left lobe of the liver. Identification in the hernial contents of the stomach or liver is considered a poor prognostic sign. Virtually all of these patients are turning bowel disorders, which also need to be corrected during surgery. The contents of the right-rear hernia is usually the right lobe of the liver and intestines.

Clinic. The severity of cardiopulmonary disorders in false diaphragmatic hernia depends not only on the degree of compression and displacement of the mediastinum, but also the depth of morphofunctional changes in the lungs and cardiovascular system, which occurred in the neonatal period as a result of compression of the lung. Approximately 30% of these children are born dead and about 35% die shortly after birth, before entering the Department of Surgery of the newborn. On the other hand, about 5-15% of patients with herniated Bogdaleka can live for months or years without obvious symptoms of the disease

Symptomatology false diaphragmatic hernia, mainly caused by the degree of compression of the chest cavity. These hernia frequently than the true lead to a compression syndrome.

Most children with false diaphragmatic hernias respiratory and cardiovascular disorders occur immediately or in the first hours after birth and are pronounced. Most often occur cyanosis and dyspnea, which are manifested in the form of attacks. This condition is called "asfiksicheskim infringement", stressing that the front act symptoms of acute respiratory and cardiovascular disease, whereas symptoms of bowel obstruction not have time to develop as the child undergoes surgery or die early from cardiopulmonary failure. On examination, in addition to cyanosis, may draw the attention of the asymmetry of the chest with bulging on the affected side. Respiratory excursion of the half chest sharply reduced. Respiration is rapid, superficial. Stomach due to move into the chest cavity organs, usually sunken, scaphoid (Fig. 1). Percussion over the corresponding half chest determined tympanitis, auscultation-a sharp weakening of breath.

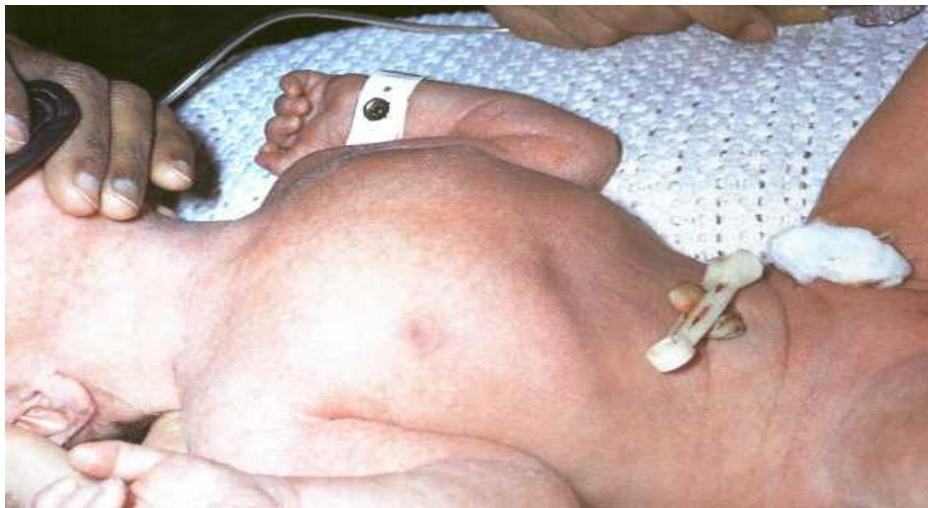

Fig. 1. Exterior false patient with congenital diaphragmatic hernia

Heart sounds in the left-side hernia defined right, indicating that the displacement of the heart in a healthy way (dekstrapozitsiya). This can sometimes give rise to misdiagnosis dekstrakardii truth. In the chest can sometimes hear the splashing or peristaltic noises.

Cyanosis attacks intensified when screamed, anxiety, feeding or changing the position of the child. Even shifting from the left side to the right could lead to increased displacement of the mediastinum and lung, and thus to a deterioration. Deterioration of the baby while feeding occurs due to the overflow of the stomach and intestinal loops located in the thoracic cavity, stomach volvulus, increasing bloating, phenomena of partial or complete obstruction of the gastrointestinal tract. Often, immediately after the birth of the child a marked cyanosis, skin and mucous dark blue or iron color, shallow rapid breathing, or rare, weak cry. Acute respiratory failure progresses very quickly. These children are usually delivered to the surgical clinic of the maternity hospital in extreme asphyxia or even agonal state. At untimely assistance and ventilation, they quickly die from hypoxia. Mortality in this group of patients can reach 70%.

Child's chances of survival increase significantly and can reach 100%, if signs of respiratory failure appear not earlier than 24 hours after birth. Such children have symptoms of respiratory disorders, shortness of breath appear and at the cry, cry, change of position. Sometimes there is persistent cough, periodically, especially after feeding, vomiting occurs. However, in some cases, these patients respiratory failure can be severe in the form of respiratory distress. Children older than 3 years are usually complain of shortness of breath, fatigue on exertion, fatigue, poor appetite, dizziness. In physical development, they are far behind their peers. Auscultatory percussion change and typically the same as those described above, but are better able to listen to the noise of peristaltic waves of displaced into the chest bowel loops.

A small number of patients with abdominal organs are not always found in the pleural cavity, and shifted back periodically. Thus there is an attack of pain on the same side, sometimes develop shortness of breath, the phenomenon of partial intestinal obstruction.

Diagnosics. Currently, diagnosis of diaphragmatic hernia can be installed prenatally by ultrasound pregnant women. Signs of pathology are polyhydramnios, the location of the stomach or intestinal loops in the pleural cavity. The reason

polyhydramnios likely are kinks in the area of the gastro-esophageal junction and / or the displacement of the pylorus of the stomach. The presence of polyhydramnios and the displacement of the stomach into the pleural cavity are poor prognostic signs that say about the great defect of the diaphragm. Mortality in this group of children may reach 70-90%. Upon detection of diaphragmatic hernia fetus should be carefully examined for the presence of sonographically defects of the spine, brain, heart and kidneys. To identify chromosomal and metabolic abnormalities perform amniocentesis or chorion biopsy. If diaphragmatic hernia is the only flaw may be considered intrauterine its correction.

After birth, the main method of diagnosis is radiography. The survey includes an overview of chest radiography and, according to testimony, radiopaque research methods, the nature of which depends on the type of alleged pathology. At the Review radiography for false diaphragmatic hernia, pleural characterized by annular or cellular enlightenment throughout the affected side of the chest (Fig. 2).

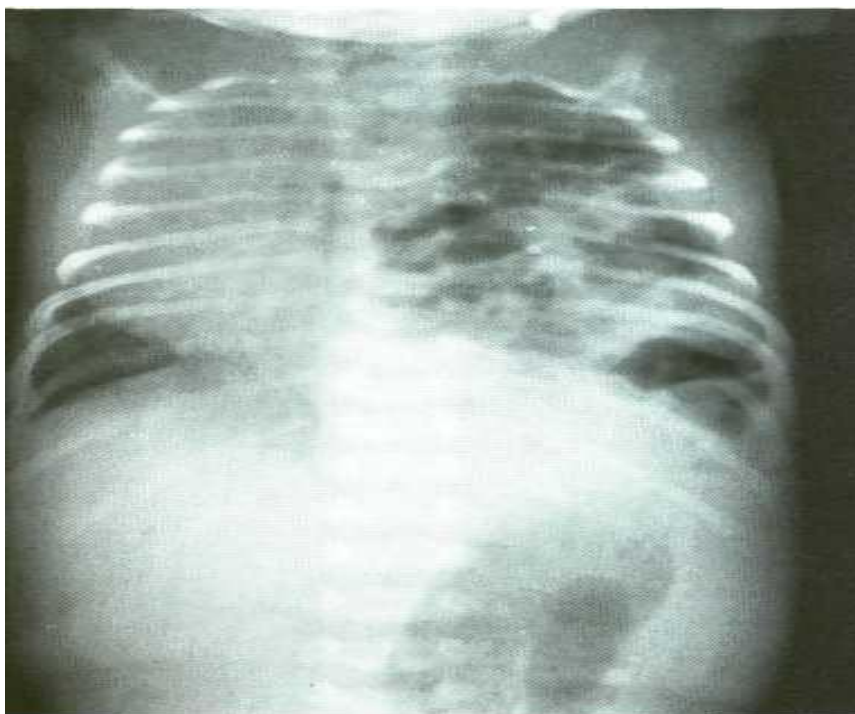

Fig. 2. Survey radiograph of a child with congenital left-sided diaphragmatic hernia. In children, the first days of life, it is usually difficult to identify the border of the collapsed lung on the affected side.

Annular shadows often have a patchy pattern without a clear contouring each cavity. Characteristic variability of the position and shape of the plot of enlightenment and darkening due to peristalsis. This sign can be established by comparing two radiographs made after a certain period of time. Shadow offset chest abdominal organs is determined not only in the projection of the pleural cavity, but also in the mediastinum. When false hernias often impossible to trace the contour of the dome of the diaphragm on the affected side, and the shadow of the intestinal loops from the chest to the projection smoothly into the abdominal cavity. At the same time there is a decrease in bowel pneumatization projection abdomen due to its upward bias. Displacement of the heart and mediastinum depends on the amount prolabirovavshih organs into the chest cavity. In infants and children during the first months of life, the displacement is so great that often seems innate dekstrakardii. Figure healthy lung amplified, sometimes reminiscent of partial atelectasis. Often you can see the mediastinal hernia.

In difficult cases, the diagnosis is facilitated by the presence of the probe in the stomach, allowing you to confirm its location in the chest. For the final conclusion, more often in older children, it is necessary to resort to contrast studies of the gastrointestinal tract. For this purpose, contrasting gastric contrast passage through the gastrointestinal tract and ergography.

Treatment. All infants with false diaphragmatic hernias require surgical treatment. An important success factor is the timing of the operation. In the past it was thought that these patients require emergency surgery, which frees up the pleural cavity and allows for straightening lung on the affected side. However, over the last 10-15 years, it became clear that an immediate correction of the defect is not always has a beneficial effect on lung function. The results of operations are largely dependent on the degree of pulmonary hypoplasia and its degree of pulmonary hypertension in a patient. Therefore, correct intensive preoperative preparation is an important factor in the survival of these patients.

PREOPERATIVE PREPARATION

In infants with diaphragmatic hernias has several features. The main purpose is to stabilize the preoperative preparation of the child to allow a radical operation. In many ways, it is determined by the degree of existing respiratory, cardiovascular and other functional disorders.

Surgical treatment. false diaphragmatic hernia in infants should be performed after stabilization.

Access may be thoracic or abdominal. Thoracic allows access to inspect and hypoplastic lung with less technical difficulties or take in to perform plastic diaphragm. Its disadvantage is the inability to perform operations simultaneously failed to eliminate rotation of the bowel or form, if necessary, ventral hernia. Easier access in abdominal organs infiltrated degrade properly arrange them in the abdomen, eliminate malrotation. Hypoplastic lung can be viewed through a defect in the diaphragm. The vast majority of surgeons prefer to use when false diaphragmatic hernia abdominal access. In older children, the operation is performed through a median laparotomy. In infancy preferred cross-sectional cross recti. Possibly, also, the use of laparoscopic techniques. In the first stage of operation the intestine and other organs in the abdominal cavity relegates. It is important to make sure that the abdominal cavity relegated spleen, which is usually the last "leave" the chest. After the removal of organs from the chest cavity should be inspected for signs of the hernia sac, which is present in approximately 20% of patients. The bag should be excised because it interferes with the straightened light and contributes to the formation of residual cyst compressing the lung. Hole in the diaphragm is firmly sutured with absorbable mattress sutures. In the absence of diaphragm muscle roller sutured to the edge. With a large hole defect should close the flap of a synthetic fabric, best Teflon mesh or patch of gorteksa. If necessary, remove the malrotation. Abdominal wound was sutured in layers tightly. Chest cavity drained thin silicone tube. Some authors recommend to drain the pleural cavity and the opposite. This avoids tension pneumothorax with pulmonary barotrauma and install the mediastinum in the midline through the manipulation of active aspiration on both sides. Often, after bringing down the intestine under the diaphragm there is a discrepancy

between the capacity of the abdominal cavity and the volume of the intestine. In these cases it is advisable to stretch the abdominal wall finger that would fit the intestine into the abdominal cavity. Optionally, you can not take in the aponeurosis, and perform with plastic cutting out the flap of both halves of the aponeurosis or sew the skin only. In rare cases, it may be necessary to stretch sewing laparotomy wound temporary patch Silastic, as it is done with omphalocele and gastroschisis. Always leave the probe in the stomach for its decompression. In the postoperative period. should continue ventilation. The concentration of PO₂ in the arterial blood should be 80 - 100 mm Hg. Art. Reduce the concentration of oxygen and respiratory rate should be slow, because even a small drop Fio₂ can lead to pulmonary vascular spasm pronounced, persistent fetal circulation rehabilitation and pulmonary hypertension. If the patient drainage installed in the pleural cavity with only the affected side, active aspiration should not apply, that would not cause displacement of the mediastinum. When bilateral drainage is sufficient to create a vacuum of 5-7 cm H₂O on the affected side and 8-10 cm H₂O - for healthy. This is usually enough to keep it in place mediastinum.

DOME OF THE DIAPHRAGM HERNIA

Dome of the diaphragm hernia in most cases are true. Hernial sac in this case defines a portion thinned diaphragm dome, which in varying degrees protrudes into the pleural cavity. These hernias are more common on the right. Their sizes can range from a small protrusion of the diaphragm to its complete relaxation when there is thinning and high standing of the entire dome of the diaphragm. Complete relaxation is more common on the left. Relaxation can be congenital, when there is a defect in the formation of the dome of the diaphragm muscle, and thoraco - abdominal partition consists of two serous layers. Secondary relaxation often occurs due to damage to the phrenic nerve generic. Usually in these cases takes place and match brachial plexus palsy Duchenne - Erbach. Phrenic nerve damage can occur in the child during an operation on the neck and mediastinum or from inflammatory processes and tumors in the area.

Rarer full defects in the dome of the diaphragm to form false hernias. In these

cases, the clinical picture of the disease and therapeutic tactics differ little from those in the rear of the diaphragm hernia. Diaphragmatic hernia with a complete absence of the dome of the diaphragm are extremely rare, accounting for about 1/7 of all false hernias. Surgery is rarely necessary to deal with this type of defect, since these children usually die in the nursing home immediately after birth. The absence of both domes of the diaphragm - even more rare malformation, which is usually described as casuistry.

Clinic. Symptoms of true diaphragmatic hernia depends on the degree of herniation and compression of the chest cavity. Unlike false hernias in children is much less marked acute respiratory syndrome and cardiovascular disease, as well as signs of obstruction or denial of bowel loops.

True for large hernias, ie significant protrusion of the diaphragm, more than half of the cases, symptoms begin to appear in children younger than 3 years, and sometimes, in 10% of cases, even in the neonatal period. Often clinically determined cyanosis and dyspnea. Do infants more vivid manifestations of the disease. Older children often mark of pain and discomfort in the chest and abdomen, especially after eating or exercise. They often vomit, especially after meals. With age, there is a tendency to reduce the severity of respiratory symptoms such as shortness of breath and cyanosis, but the lag in physical development continues to grow, there is a deformity of the chest, are often marked by recurrent pneumonia.

Auscultation and percussion revealed some relaxation and breathing tympanitis on the affected side. In some cases, when filling out the liquid contents of the intestinal loops percussion sound will change. When the left-side hernia percussion and palpation is not possible to determine the spleen. Sometimes it is possible to note the asymmetry of the abdomen.

More than 50% of observations true diaphragmatic hernia, pleural, especially when limited protrusion of the dome of the diaphragm, the symptoms are completely absent. This is associated with a stable position of invading in the hernial sac and the absence of a lot of pressure on the thoracic organs. The physical and auscultatory data in true small hernias do not reveal any abnormalities. Children may not outwardly differ from healthy, well-developed and not lag behind in development from their peers.

Diagnostics. X-ray picture of the true diaphragmatic hernia is characterized by the presence of round or oval in the shadow of the hernia sac with a smooth contour limiting prolabirovannye abdominal organs. This circuit formed hernia sac, known as the boundary line.

Small true hernia almost twice as likely to occur on the right than on the left. They are characterized by the protrusion of a limited portion of the diaphragm. Mobility of the diaphragm or little changed somewhat limited. Offset mediastinum and heart absent or expressed moderately. Large hernias almost always observed on the left. True hernia of considerable size can capture 30 to 80% of the area of the diaphragm. They can be located at the front and rear parts of the diaphragm. Hernial sac is projected on the background of the pulmonary field and forms a boundary line or oval shape polukrugloy. Under these hernias collapsed lung and heart displacement on radiographs always expressed. The angle between the normal of the diaphragm and the bag in the hernial traced bad, especially on direct radiographs in the lateral projection seen it better. Usually angle hernial at large hernias stupid, but unlike the relaxation of the diaphragm is always emphasized and can be defined in the study of the gastrointestinal tract with barium meal.

When right-hand drive contents of the hernia sac is most often the liver. When a portion of the liver is included in the hernial sac, it takes a hemispherical shape, his shadow becomes dense and intense and merges into the lower regions of the main shadow liver. Rarely between the diaphragm and liver colon prolapses. In this case, the shadow of the liver will be pushed downwardly. Left the contents of the hernia sac is most often the bottom of the stomach and / or small intestine and colon, along with the spleen. In these cases, the background of the pulmonary field below the boundary line defined by large - and melkopyatnistye cavity. Sometimes stomach almost completely fills the hernial protrusion and looks like a large single cavity with a fluid level. Depending on the degree of filling of the stomach and intestine radiographic picture changes. Movement of the hernia sac during breathing sharply limited, and sometimes are rather paradoxical. In some cases, aid in the diagnosis may have an ultrasound

exam. Some authors consider it to be very useful in the differential diagnosis of true and false hernia of the diaphragm. For differential diagnosis of diaphragmatic hernia with tumors, sequestration, congenital cystic lung inflammation or recommend the use of pneumoperitoneum, computed tomography and isotope liver scan.

FRONT HERNIA OF THE DIAPHRAGM

Herniation of the anterior diaphragm and are retrosternal frenoperikardialnymi.

Retrosternal hernia (true) and separated into retrosternal retrosternal-rib. Hernial protrusion of the abdomen in the anterior mediastinum occurs through a defect of the diaphragm behind the breastbone (the gap Larrey) to form a hernia of Morgagni. Hernial sac forms the parietal peritoneum. Some left-wing authors Larrey hernia hernia calls, right-handed - Morgagni hernia. These hernias occur in children up to 20 times less than the rear of the diaphragm hernia. Their contents are usually part of the liver, small intestine and colon, spleen less.

Frenoperikardialnye hernias are false, the defect is located in the tendon of the diaphragm and the adjoining section of the pericardium. Through this defect abdominal organs can move directly into the cavity of the pericardium, and vice versa, partially dislocating heart defect through the diaphragm into the abdominal cavity (retrograde hernia).

Retrosternal defect in the pericardium and diaphragm can be combined with epigastric epigastric hernia diastasis or umbilical cord. While the distal portion of the sternum is shortened or split, are often marked by congenital heart defects - defects partitions and tetralogy of Fallot.

RETROSTERNAL HERNIA

Clinic. For retrosternal (parasternal) hernias are more common symptoms of disorders of gastro - intestinal tract. Compression of the lung or heart in this pathology is usually small. The child periodically have pain and discomfort in the epigastric region,

and sometimes vomiting. Shortness of breath, coughing, cyanosis are rare. Almost 50% of this defect may not manifest clinically. On examination marked bulging of anteroinferior sternum. Percussion and auscultation method can determine tympanitis weakening of the heart sounds, the absence of cardiac dullness. If the hernial sac filled gland or partially otshnurovavsheysya liver then, along with the weakening of the heart sounds will be marked shortening of percussion sounds. When retrosternal hernia often found sochetannye anomalies, particularly heart defects.

Diagnostics. When retrosternal hernia on plain film defined shadow or semi-oval, usually pear-shaped in the field of chest - costal space. In direct projection it is projected onto the shadow of the heart or is paramediastinalno. In the lateral projection shadow hernia superimposed on the anterior mediastinum and merges with shadow heart. When parasternal location can sometimes be traced boundary line (bag) as a semicircle in kardiodiafragmalnom corner. If the hernial sac are hollow organs within the boundary of the bag on the background of lung or heart disease, can be detected Coarse shadow. In some cases, you can see and typical haustration colon. Sometimes only the gland prolapses. Shadow there may be dense, without cellular enlightenment. As with other types of diaphragmatic hernias, there is variability in X-ray pictures. The diagnosis is finally confirmed when contrast study of gastro - intestinal tract with barium meal.

With all hernias, contents of which are dense bodies with differential - diagnostic purposes, you can use the imposition of pneumoperitoneum. Surrounds the air at the hernial contents, which clearly indicates that it belongs to the abdominal organs.

Treatment. Operative treatment of retrosternal hernia performed by upper midline laparotomy. After opening the abdominal cavity visiting anterior diaphragm. In the hernial sac, located in the anterior mediastinum, usually enters a loop of the transverse colon, which relegates to the abdominal cavity. Hernial sac can not excise. Diaphragm in the parietal defect sutured individual seams soft tissue anterior chest wall. Should not be hemming rear edge hernial aponeurosis to the anterior abdominal wall. Such seams, although reliable, can sometimes lead to tension pericardium. In recent years, carried out several operations over the retrosternal hernia using

laparoscopic techniques. Low-traumatic surgery, and holding her greatly facilitated by the fact that the contents of the hernia sac spontaneously reduce a into the abdominal cavity during filling it with gas. Defect in the diaphragm sutured separate seams that after through the anterior abdominal wall is fastened subcutaneously.

FRENOPERIKARDIALNYE HERNIA

Clinic. Leading symptoms are cyanosis, dyspnea, anxiety, vomiting less, resulting in displacement of pericardial bowel loops. Symptoms often occur in the early weeks and months of life, with age, they do not disappear. Possible infringement dropped pericardial bowel loops. On examination, particularly in children after 1-2 years of life, revealed a protrusion of the chest. Possible asymmetry of the abdomen indrawing in the left hypochondrium. When percussion the disappearance of cardiac dullness. Heart sounds are muffled.

When retrograde frenoperikardialnyh hernias when there is prolapse of the heart through the defect, to the fore cardiovascular disorders. This type of diaphragmatic hernia most often accompanied by multiple malformations (heart defects, transposition of the great vessels, polycystic kidney disease).

Diagnostics. When X-ray examination of the patient determined cellular enlightenment on the background cardiac shadow. In children, the first hours of life, when the intestines are not yet filled with gas, the diagnosis is extremely difficult. Assistance can contrast study of the gastrointestinal tract, but the baby is not always possible to carry out additional procedures.

Treatment. Surgery alone, or by verhnesredinnoy transverse laparotomy. When frenoperikardialnyh hernia hernial sac is completely absent, the abdominal organs are moved in pericardial cavity through a defect in the anterior tendinous center of the diaphragm. After being relegated hernial contents into the abdominal cavity, the defect in the diaphragm can take in individual seams. However, most surgeons prefer to perform plastic defect patch of foreign material (gorteks or preserved dura mater). This is for two reasons. First, if the defect is large, simple suturing it can lead to compression of the heart pericardium. Second, constant heartbeat in joints often lead to their failure

and recurrence of the hernia.

HIATAL HERNIA

Hiatal hernia are true and are divided into two large groups - esophageal and paraesophageal. Most often, about 80-90% of cases occur esophageal hernia. When esophageal hernias esophageal-gastric junction, together with the stomach, through the esophageal opening moves above the diaphragm. The esophagus normally is of normal length, but it is due to upward displacement can be deformed and bent. For paraesophageal hernias characteristic displacement of the stomach and / or other abdominal organs (omentum and intestine) up next to the esophagus. Esophageal-gastric junction, in this case, is located on the usual location. Hiatal hernia are not always fixed. The bias up and shape of the stomach may vary depending on the position of the patient, and the degree of filling of the stomach contents (food or dense liquid, gas). Moving gastric hiatal hernia can be partial or complete.

ESOPHAGEAL HERNIA

Clinic. The clinical picture of esophageal hernia is mainly due to gastroesophageal reflux (GER), resulting from dysfunction of the cardiac portion of the esophagus. In cases where a child to maintain normal function of the lower esophageal sphincter, the disease may be asymptomatic. Symptoms of the disease appear in most cases early, almost half of the cases in infancy. As with gastroesophageal reflux disease (GERD) without esophageal hernia in children can be divided into three main clinical syndromes: vomiting, esophagitis and respiratory complications that often occur in the same patient. It should be noted that for esophageal hernia clinical symptoms are more pronounced and less amenable to conservative and medical treatment. Therefore, the presence of symptoms of GER in children with esophageal hernia is usually an indication for correcting and antireflux surgery. Restlessness and vomiting are the leading symptoms of the disease in young children. Vomiting often associated with food intake, is the most diverse in nature, can be plentiful or as regurgitation. In vomit increasingly finding gastric contents, sometimes

mixed with bile. Due to the constant and persistent vomiting children do not add weight. In some periods, especially in the first months of life, lose weight and even exhausted. Older children often worse physically developed. On the evidence of esophagitis, abdominal pain and heartburn complain mostly older kids. Pain usually occur after meals, or in a prone position when the torso is tilted, due to wicking of gastric contents into the esophagus and its corrosive effects on the mucosa. Erosive and ulcerative esophagitis can cause hidden or "occult" bleeding into the lumen of the gastrointestinal tract in approximately 50% of children. The result is a chronic iron deficiency anemia, which causes sometimes difficult to establish. Massive esophageal bleeding as hematemesis or melena for esophageal hernias are not typical. Serious complication of peptic esophagitis are strictures of the esophagus, usually due to scarring. These strictures often short and located in the lower esophagus. Often, about 30-40% of cases, especially in young children, there are recurrent aspiration pneumonia. Frequently encountered and other respiratory pathology - tracheobronchitis, night cough, asthma. Approximately 15% of patients is formed ENT pathology - laryngitis, pharyngitis, otitis, sinusitis, etc.

Diagnosics. Currently, the diagnosis of esophageal hernias using X-ray method, fibroezofagogastroduodenoscopy (FEGDS), 24-hour esophageal pH-metry, manometry and esophageal scintigraphy. Diagnose esophageal hernia allow x-ray examination, and scintigraphy FEGDS. The rest of these methods make it possible to evaluate different aspects of the ERT.

The main radiological signs of esophageal hernia is the displacement of the stomach with his cardiac department above the diaphragm (Fig. 3). Unlike ampoules of the esophagus, which has the form "tsistoida" with smooth contours for esophageal hernia characterized by uneven edges and usually greater transverse dimension. Furthermore, oesophageal hernia detected at any position of the body, whereas the esophagus formed vial in a horizontal position of the patient.

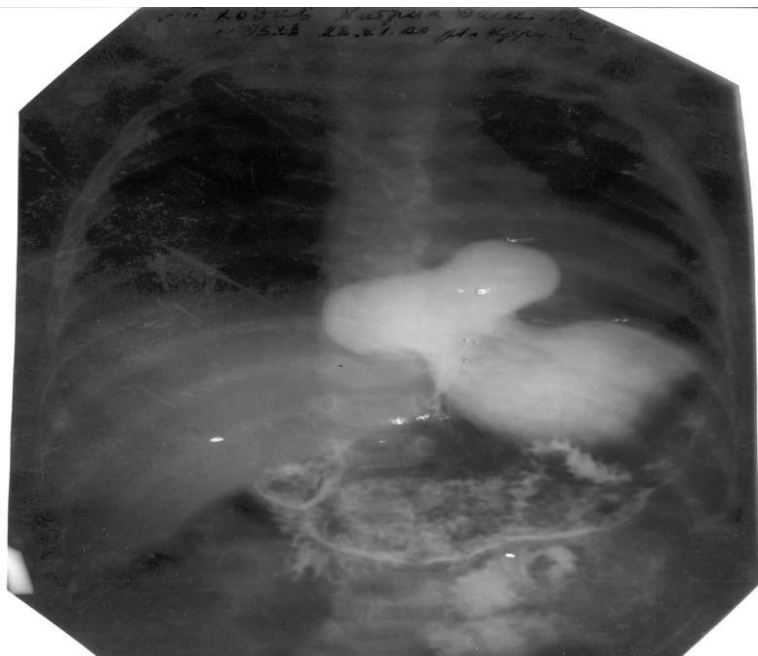


Fig. 3. Contrast radiograph esophageal hernia in a child 7 months.

Other radiological signs of esophageal hernias are tortuous course of the esophagus due to its upward displacement, obtuse angle confluence of the esophagus to the stomach, esophagus high inflow into the stomach, coarse longitudinal folds of mucous membrane in epiphrenic portions that are a continuation of the folds of the stomach.

To the failure of the cardia with esophageal hernia indicate radiographically detectable gastroesophageal reflux spontaneous and have a positive provocative, load or water-siphon test.

Fibroezofagogastroduodenoscopy (FEGDS). For esophageal hernias typical offset dentate line transition esophageal epithelium in the stomach above the diaphragm with prolapse folds of the stomach into the esophagus. In the distal esophagus is marked narrowing of the two corresponding to the level of the cardia of the stomach and the diaphragm. Prolapse folds particularly good at deducing fiberscope revealed from the stomach into the esophagus and air insufflation. It should also pay attention to the signs of failure of the cardia - gaping sockets, extension of the esophageal lumen and the leaking of gastric contents into it.

FEGDS plays an important role in the diagnosis of complications of GER - esophagitis, peptic strictures of the esophagus and Barrett's epithelium.

The majority of patients with hiatal hernia and peptic esophagitis ERT varying severity affects the lower third of the esophagus over a few centimeters, or limited cardiac area. Mucosa in this area can be clearly hyperemic, bleed easily. In severe cases, it can be seen erosive surface in some places covered with fibrinous films. However, significantly

more likely due to changes in the mucous ERT small or absent. In these cases, the diagnosis can be confirmed by histological examination. Mucosal biopsy also shows the suspected such a severe complication of esophagitis, Barrett's esophagus.

Confirm the presence of GER in patients with hiatal hernia can be using 24-hour pH-metry, manometry and esophageal scintigraphy.

Treatment. Esophageal hernias can be conservative and operative. Conservative and medical treatment is indicated in small uncomplicated hernias. These methods are aimed at prevention and treatment of GER (VV Troyan 2003), but does not correct the underlying hernia. They include a elevated position, diet and fractional feeding prescriptions increasing tone of the lower esophageal sphincter (prokinetics) and drugs reduce the aggressiveness of gastric contents (antacids, H2 blockers of histamine, proton pump inhibitors).

Surgical treatment. Surgical treatment is required for all esophageal hernia do not respond to conservative treatment, occurring with severe clinical picture of the ERT, peptic and / or respiratory complications.

Surgery is performed by open laparotomy or laparoscopy. Torakotomy access is rarely used, usually for recurrent hernias when there is extensive adhesions in the abdominal cavity.

After laparotomy verhnesredinnoy left lobe of the liver and mobilize allot right. The stomach is pulled down for a large curvature, while offering access to hiatal. Gastric cardia send down into the abdominal cavity. Hernial sac completely or partially excised. Is usually sufficient to produce a circular partial excision of the bag in the gastric cardia and hiatal. Complete removal of the hernia sac is not necessary. Esophagus move in the anterolateral division expanded aperture. Then, depending on the age of the child, hold the stomach probe № 18-36 F. In adults use balonnye dilators or bougies № 40-60 F. Under the supervision of a finger on the edge of esophageal hiatal behind impose nodal non-absorbable sutures, bringing together the legs diaphragm. No seams should be tied tightly to not cause sclerosis muscular legs. Esophageal opening is sutured so that its edge between the esophagus and passed the fingertip.

Surgical intervention should be combined with antireflux surgery. Even if the

reflux was not until the operation is very high probability of its occurrence after manipulation on the esophageal-gastric junction.

The literature describes many ways of surgical treatment of GERD. Practice shows that the best method is Nissen fundoplication overlay short and wide, floppy cuff. To do this, conducted extensive mobilization of the stomach, the greater curvature to approximately the level of the gate of the spleen. In older children and adults can apply option Rosetti, without broad short ligation of vessels, because the stomach they are large enough to be used for fundoplication only its bottom. The probe № 18-36 F imposed the maximum possible free fundoplikatsionnuyu cuff 2-4 sutures, 2-4 cm in length, depending on the age of the child. Cuff fixed to the esophagus and diaphragm to prevent it slipping. Indication for pyloromyotomy is a violation of gastric emptying, detectable before surgery. At cicatricial narrowing of the esophagus caused by GERD, the need for resection is usually not. As our experience and the experience of other clinics, eliminating reflux leads to regression of stenosis and improve patency of the esophagus.

In recent years, the above operation is performed by laparoscopy. The basis for this are the general advantages of laparoscopic surgery - no pain, the possibility of early to start breast-feeding, shorter hospital stay, a good cosmetic effect, reducing adhesions in abdominal. During laparoscopic fundoplication there was no need to mobilize the left lobe of the liver. Good visualization due to increased intervention allows more anatomic. It should be noted that the younger the child, the less time is usually required for laparoscopic Nissen fundoplication.

PARAESOPHAGEAL HERNIA

Clinic. Paraesophageal hernia is rare in children. In this form of possible infringement of hernial contents - stomach and intestinal loops. However, most often with incomplete recurrent volvulus mesentericoportal-axial type, when the stomach is folded along an axis transverse to the center held a small to a large curvature. In this pyloric part of the stomach moves up and is near the cardia. Leading symptoms in gastric volvulus are pain, swelling in the epigastrium, nausea and vomiting.

When Paraesophageal the conditions not only for inversion but also to bend the stomach

that can lead to disruption of the passage, stagnation and vomiting. Common symptoms in this case, are as malnutrition, child falling behind in physical development, exhaustion, anemia, fatigue, decreased appetite.

Diagnostics. X-ray picture paraesophageal hernia has features already at scoping study. The displacement in the posterior mediastinum fundus on plain film defined cystic formation, often with the liquid level. Stomach may be to the right or left side of the mediastinum shadow. In lateral view, this education is shifted backward from the mediastinum. Gas bubble stomach located in the abdominal cavity is reduced or absent. Mobility of both domes of the diaphragm is not broken. Shadow of the hernia sac usually coincides with shadow prolabirovannogo stomach and repeats its contours. Accurate diagnosis allows radiopaque study of the gastrointestinal tract, including the use of barium enema.

Fibroezofagogastroduodenoscopy. When paraesophageal hernias during fundus examination "on the reverse," near the entrance of the esophagus is usually detected a crack through which part of the stomach "leaves" in the posterior mediastinum. This is strong evidence of a hernia offset fundus. Full examination must necessarily include research on ERT, esophagitis, and comorbidity of the stomach and duodenum.

Treatment. The presence of paraesophageal hernia is an indication for surgery. Intervention carried out through the abdominal access. Contents of the hernia sac relegate into the abdominal cavity. Suturing extended hiatal can perform on Harrington, front and left of the esophagus, or better, by Allison - behind the esophagus, which is displaced anteriorly and to the left. Surgery necessarily be combined with antireflux surgery (Nissen fundoplication), as described above. In recent years, this operation is often performed laparoscopically.

Shape control of knowledge, skills and abilities

- Oral
- Written
- Testing
- Decision of situational problems
- Demonstration of skills mastered

Evaluation criteria of the current control

Progress of number (in% and score ah)

Score Level of students' knowledge

1. 96-100 Excellent - to be able to make a conclusion and decision

- Be able to think creatively
- Be able to independently survey
- Be able to practically apply the knowledge
- To understand the essence
- Know and tell
- Have an idea

2. 71-85 Well- able to think creatively

- Be able to independently survey
- Be able to practically apply the knowledge
- To understand the essence
- Know and tell
- Have an idea

3. 55-70 Satisfactory - be able to independently survey

- Be able to practically apply the knowledge
- To understand the essence
- Know and tell
- Have an idea

4. 54 - Disappointing and below - do not have an accurate idea

- Knows

TEST QUESTIONS

1. Characteristic radiographic sign diaphragmatic hernia:

- a) availability of cellular zone enlightenment and the fluid level in the lungs;
- b) The shaded area of the lungs;
- c) X-ray attenuation in the lower lung;
- d) mixing the mediastinum towards the hernia;
- d) the availability of precise contours of the diaphragm.

2. At what form diaphragmatic hernia requires emergency surgery:

- a) when the true hernia diaphragm dome
- b) at the diaphragmatic hernia, esophageal holes:
- c) for large true diaphragmatic hernia;
- g) upon relaxation of the diaphragm;
- d) for false-pleural diaphragm hernia.

3. Symptom characteristic "Asfiktikcheskoy breathlessness":

- a) increase in dyspnea and cyanosis;
- b) the presence of symptoms of intestinal obstruction;
- c) the symptoms of cardiovascular disease;
- g) clinical toxicity-exsiccosis;
- d) hemorrhagic syndrome.

4. Neonates concern during the development of cyanosis for what disease is characterized by:

- a) esophageal tracheal fistula;
- b) voronkaobraznaya chest deformity;
- c) subdural hematoma;
- g) diaphragmatic hernia;
- d) doubling the aortic arch.

5. Leading symptom of congenital diaphragmatic hernia:

- a) respiratory failure
- b) violation of the assimilation of food eaten;
- c) violation of urination;
- g) deformity of the chest;
- d) severe pain in the chest.

6. Main diagnostic method for congenital diaphragmatic hernia:

- a) ultrasonography;
- b) stenosis of the esophagus;
- c) the esophageal-tracheal recanalization of the fistula;
- d) recurrent aspiration pneumonia;

d) dysphagia due to functional disorders.

7. Characteristic symptom of diaphragmatic hernia for-hiatal:

- a) shortness of breath;
- b) vomiting with blood
- c) vomiting bile;
- g) cough;
- d) heart failure

8. Typical symptom for false diaphragmatic hernia:

- a) tremor;
- b) Hyperthermia;
- c) respiratory failure;
- d) symptoms of intestinal obstruction;
- e) symptoms of renal insufficiency.

9. Diaphragmatic hernia this:

- a) displacement of the lung into the abdominal cavity;
- b) mediastinal shift toward pathology;
- c) mediastinal shift in a healthy way;
- g) mediastinal shift toward the abdominal cavity;
- d) passage of the abdominal cavity in the chest cavity.

10. The main diagnostic method esophageal hernia - diaphragmatic holes

- a) ultrasound of the chest;
- b) Review a chest radiograph;
- c) gastroduodenoscopy;
- g) contrast study zhlyudka;
- d) laboratory testing of vomit.
- d) diverticulum of the esophagus.

CASE PROBLEM

1. Turned parents 1-month-old child with a history of vomiting. During the inspection there in vomit blood. What disease should think?
2. At 1.5 month old child has the following symptoms: a rare symptom of vomiting

becomes more frequent, in addition scales very slowly, often repeated pneumonia, vomit in there blood and mucus during feeding worries during sleep rarely kaschlietsya. Verify the diagnosis:

3. The hospital to take 1.5 month old baby diagnosed with bilateral pneumonia. Night during a cough sometimes cyanosis, apnea short, rapid pulse. Respiration is rapid, with the participation of auxiliary muscles. On radiographs in the left pleural cavity defined by the air bubbles. Your preliminary diagnosis. How should we treat?
4. The hospital to take 2 year old child diagnosed with bilateral pneumonia. Night during coughing in a child marked cyanosis, vomiting, pain in the left side of the chest. Your preliminary diagnosis. What should I do to install an accurate diagnosis. How should we treat?
5. The clinic during an inspection at the 4-month newborn lungs listened to suspected diaphragmatic hernia. Your further tactics?
6. A newborn immediately after birth rapidly growing shortness of breath and cyanosis. List the disease of the newborn, accompanied by the syndrome.
7. Newborn on the second day of life suddenly started to increase respiratory failure progressed dyspnea, cyanosis. Examination revealed the child's condition is extremely serious, dyspnea, cyanosis, heart rate 196 beats per minute, thready. When percussion revealed mediastinal shift to the left, to the left - normal lung sounds right - tympanitis all lung fields. Auscultation of the left - vesicular breathing right - breathing, sharply weakened. Which diseases physician should consider? What are the necessary additional studies?
8. Newborn 6 hours after birth gradually increase respiratory failure - shortness of breath, cyanosis. Repeated examination noted a gradual shift to the right heart. The left half of the chest several bulging, behind in the act of breathing, percussion normal lung sounds right, left - shortening lung sound periodically appears tympanitis. Auscultation left unable to hear "gurgling" noises. On plain film chest mediastinum toward the right, the left and 2 ribs defined variegated air cavities. A presumptive diagnosis? Diagnostic and therapeutic tactics?
9. Neonatologist you caused in the nursery, where a child born with a body weight of

3000 g at 12 hours after birth, became progressively increasing cyanosis, vomiting occurred. Child became lethargic, weak cry. Breathing newborn surface, 60 min, auxiliary muscles involved, the left half of the chest inflated, stomach in, due to asymmetric protruding edge of the liver.

Your assumptions, accurate diagnosis, tactics?

10. Complaints child 3 years for Intermittent abdominal pain, weakness, fatigue, while running and physical exertion. Boy behind in physical development, the left half of the chest behind in breathing, land shortened percussion sound alternate with the tympanic, auscultation - breathing weakened, here bowel sounds are heard.

Preliminary diagnosis, accurate diagnosis, tactics?

THEORETICAL ISSUES

1. Classification of congenital diaphragmatic hernia.
2. Clinic and diagnosis of true congenital diaphragmatic hernia.
3. Clinic and diagnosis of congenital diaphragmatic hernia false.
4. Diagnosis and differential. diagnosis of congenital diaphragmatic hernia
5. Treatment of congenital diaphragmatic hernia.
6. Complication of congenital diaphragmatic hernia.
7. Dispensary and reabilitatsiya patients with congenital diaphragmatic hernia.

PRACTICAL SKILLS

1. Methods of study patients with suspected disease of the chest.
2. Conduct palpatsii, percussion, auscultation of the chest.
3. Conduct radiography, tomography of the thorax.
4. Contrast X-ray examination of the gastrointestinal tract
5. Read X-ray picture of patients.

REFERENCES

- 1.Ashkraft KW, Holder TM "Pediatric Surgery". T. 1, 2, 3. St. - Petersburg, 1996, 1997.
- 2.Bairov GA, Doroshevskaya YA, TK Nemilova Atlas operations in newborns. L., Medicine, 1984.
- 3.Bairov GA Emergency neonatal surgery. L., Medicine, 1963.
- 4.Bairov GA Surgery malformations in children. L., Medicine, 1963.
- 5.Bairov GA Emergency surgery in children. L., Medicine, 1983.
- 6.Bairov GA Emergency surgery in children. L., Medicine, 1997.
- 7.Doletsky SY Diaphragmatic hernia in children. M., Medicine, 1968.
- 8.Doletsky SY, YF Isakov Pediatric Surgery. / Guide for Physicians /. W 1-2. M., Medicine, 1970.
- 9.Doletsky S. Ya Gavryushov VV, VG Hakobyan Neonatal surgery / Guide for Physicians /. M., Medicine, 1976.
- 10.Isakov YF Surgical diseases in children. M. Medicine in 1998.
- 11.Isakov YF "Surgical diseases of childhood" / in 2 volumes, the textbook / M. Geotarmed, 2004.
- 12.Isakov YF, YM Lopoukhine "Operative Surgery and Topographic Anatomy of Childhood" M. Medicine, 1989.
- 13.Isakov YF, Stepanov E.A, Krasouskaya TV Abdominal surgery in children. / Management / M. Medicine, 1988.
- 14.Isakov YF, E.A Stepanov, VI Geraskin Guide thoracic surgery in children. M. Medicine, 1978.
- 15.Isakov YF Pediatric Surgery. / Tutorial /. M Medical, 1983.
- 16.Sulaymonov A. boshkalar Islands. "Bolalar hirurgiyasi." / Darslik /, Tashkent, 2000.
- 17.Struchkov VI, Pugachev AG Pediatric Thoracic Surgery. M. Medicine, 1975.
- 18.Harrison M.R., Langer J.C., Adzick N.S. e.a. Correction of congenital diaphragmatic hernia in utero. Initial clinical experience. // J. Pediatr. Surg. - 1990, v. 25, n. 1. - P. 47-53.
- 19.Hedrick M.H. Estes J.M., Sullivan K.M. e.a. Plug the lungs until it grows (PLUG): a new method to treat congenital diaphragmatic hernia in utero. // J. Pediatr. Surg. - 1995,

v. 29, n. 5. - P. 347-353.

20.Puri P. Epidemiology of congenital diaphragmatic hernia. // Cong. Diaphr. Hernia. - Basel, 1989. - V. 24, p. 22-27.

21.M.I. Rowe e.a. Essentials of Pediatric Surgery - "Mosby", St. Lous, Baltimore, 1995.

22.K.J. Welch e.a. Pediatric Surgery-Year Book Med. Publ. ", Chicago, 1998.-v. I.

23. E-mail: hirurgiya-uz@mail.ru

24. [Www. med lit.](http://www.medlit.ru)

25. [Www.Ziyo.net](http://www.Ziyo.net)

26. [Www.mediasphera.aha.ru / surgery / surg-mn.htm](http://www.mediasphera.aha.ru/surgery/surg-mn.htm)

27. [Www.mediasphera.aha.ru / pediatr / ped-mn.htm](http://www.mediasphera.aha.ru/pediatr/ped-mn.htm)